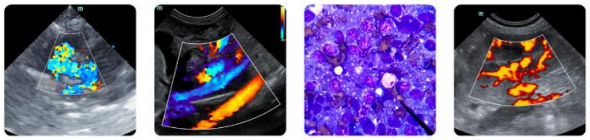

PATIENT
Harlee Cruz

SPECIES
Canine

BREED
Mixed

SEX
FS

AGE
9 y

WEIGHT
17.8 lb

INTERPRETED BY
Keith Blass, DVM, MS, DACVIM (Cardiology)

IMAGING PERFORMED BY
Gabriel Ferrer, DVM

HOSPITAL NAME
Pulse Pet Ultrasound Services

REFERRING VET
Dr. Roman

INVOICE

DATE
6/5/26

PRESENTING CLINICAL SIGNS

Excessive panting for years. Radiographs showed possible pleural effusion and tracheal collapse. Started on a trial of furosemide and Clavamox.

ECHOCARDIOGRAPHIC FINDINGS

2D, M-mode, and Doppler study.

Left atrial size is normal. The mitral valve leaflets are mildly thickened, and a mild jet of mitral regurgitation is present. Left ventricular dimensions are normal. Left ventricular systolic function is hyperdynamic. The aorta and aortic valve are normal. Right atrial and right ventricular dimensions are normal. The tricuspid valve appears normal, though trace tricuspid regurgitation is present. The pulmonary artery and pulmonic valve are normal. No shunting lesions are visualized. No heartworms are visualized. No pericardial effusion or cardiac masses are seen.

ECG during echo: Sinus rhythm

LA – 26.3 mm
LVIDd – 26.8 mm
LVIDs – 14.4 mm
FS – 46.3%
RA – 16.2 mm
LVOT – 1.28 m/s
RVOT – 1.28 m/s
TR – 3.17 m/s

ASSESSMENT/RECOMMENDATIONS

Degenerative mitral valve disease – stage B1

This examination demonstrates mild regurgitation of blood across Harlee's mitral valve resulting from degenerative valve disease. The hemodynamic effects of the regurgitation also appear to be mild at present, as Harlee does not have secondary dilation of either of her left heart chambers, and her left ventricular systolic function is well-preserved. Given the absence of left heart chamber dilation, Harlee's current risk for the development of left-sided congestive heart failure appears to be low, therefore, this is unlikely to be the cause of her panting. While I don't appreciate pleural effusion in Harlee's radiographs, the absence of right-sided cardiac dysfunction in this exam indicates that a cardiac reason for the development of pleural effusion does not appear to be present.

While furosemide can be continued if it results in clinical improvement, no specific indication for any cardiac therapy is appreciated in Harlee's echocardiogram.

A recheck echocardiogram is recommended in 6 months to monitor for disease progression.

SonoPath
FOSTERING THE ART OF VETERINARY MEDICINE™

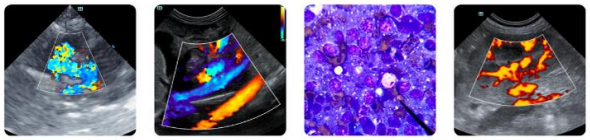

Clinical Sonography & Telecytology
Educational Teleconsultation Services™

SonoPath.com info@sonopath.com 1.800.838.4268

PATIENT

Harlee Cruz

SPECIES

Canine

BREED

Mixed

SEX

FS

AGE

9 y

WEIGHT

17.8 lb

INTERPRETED BY

Keith Blass, DVM, MS, DACVIM (Cardiology)

IMAGING PERFORMED BY

Gabriel Ferrer, DVM

HOSPITAL NAME

Pulse Pet Ultrasound Services

REFERRING VET

Dr. Roman

INVOICE

DATE

6/5/26

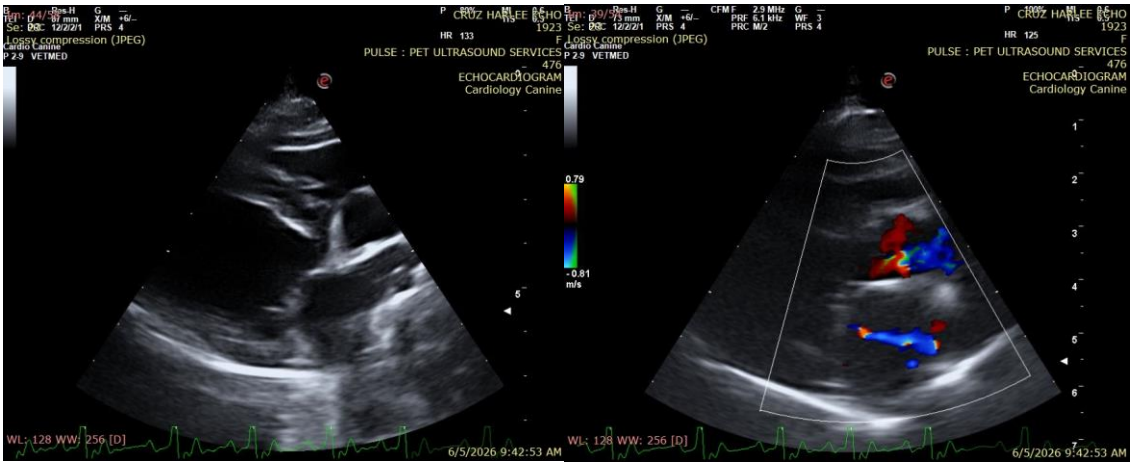

The information and recommendations provided are based on the images presented by the referring veterinarian/sonographer. No evaluation can be communicated regarding pathology that was not visible in the image/video clips provided.

Thank you for this referral. If the clinical or image interpretation does not parallel your findings or if I can be of any further assistance please contact me.

Keith Blass, DVM, MS, DACVIM (Cardiology)info@SonoPath.com